

# Sclerosing bone dysplasias: neurologic assessment and management

Louis M. Hofmeyr<sup>a</sup> and Herman Hamersma<sup>b</sup>

## Purpose of review

Sclerosing bone dysplasias are rare genetic disorders of bone remodeling in which excessive bone formation takes place, resulting in encroachment on neural structures. The infant usually appears normal at birth, and the first sign of a problem only comes when a neurologic deficit develops, usually in the form of an acute facial palsy. Although less than 300 cases have been published, these conditions should always be considered in the differential diagnosis of facial nerve palsy, especially in children.

## Recent findings

This review highlights the neurologic presentation and assessment as well as the management of sclerosing bone dysplasias. An exciting development is the recent discovery of the sclerosteosis (SOST) gene, which is involved with excessive bone formation in sclerosteosis and Van Buchem disease. Researchers in bone metabolism and pharmaceutical companies are now utilizing this knowledge to develop a medicine for osteoporosis.

## Summary

In children and young adults an acute facial palsy, especially if it is recurrent, as well as a conductive hearing loss may be the first sign of a sclerosing bone dysplasia.

## Keywords

facial paralysis, sclerosing bone dysplasias, sclerosteosis, osteopetrosis, hyperostosis corticalis generalisata, Van Buchem disease, diaphyseal dysplasia, Camurati-Engelmann disease, craniometaphyseal dysplasia, hearing loss

Curr Opin Otolaryngol Head Neck Surg 12:393–397. © 2004 Lippincott Williams & Wilkins.

<sup>a</sup>1 Military Hospital, Thaba Tshwane, Pretoria, South Africa, and <sup>b</sup>Otologist, Flora Clinic, Florida, South Africa

Correspondence to Louis M. Hofmeyr, PO Box 14033, Clubview 0014, South Africa  
Tel: +27123140442; fax +27123140446; e-mail: ahofmeyr71@hotmail.com

Current Opinion in Otolaryngology & Head and Neck Surgery 2004, 12:393–397

© 2004 Lippincott Williams & Wilkins  
1068-9508

## Introduction

Sclerosing bone dysplasias are uncommon genetic disorders characterized by increased skeletal density and bony overgrowth due to a defect in the remodeling of bone. Not only does the enlarged bone press on the brain and spinal cord, but cranial and spinal nerves are at risk at the exit foramina from skull and spinal column. The bone pathology is usually not suspected until a neurologic deficit develops in a young child. A facial nerve palsy, instead of developing gradually, presents as an acute paralysis, identical to Bell palsy. A classification of the sclerosing bone dysplasias is presented in Table 1. The purpose of this review is to discuss the literature on the neurologic assessment and management of this group of bone disorders.

## Background

In 1904 Professor Albers-Schönberg of Hamburg described a patient suffering from a benign form of thickened and very strong hard bone. After his publication the terms osteopetrosis, marble bone disease, and Albers-Schönberg disease were often used. This first patient was later identified as having suffered from the benign form of osteopetrosis. Marble bone disease is now only used as a nonspecific collective name for the skeletal dysplasias with dense bones, and the name Albers-Schönberg disease only in its historical perspective. Various other skeletal dysplasia syndromes were subsequently identified. It is now possible to make exact diagnoses of the various genetic entities by means of radiographic skeletal surveys as well as DNA investigation. A skeletal survey will show dense bones and abnormal modeling of the long bones, hands, and spine. Detailed descriptions of these conditions can be found in the database of OMIM (Online Mendelian Inheritance in Man) at <http://www3.ncbi.nlm.nih.gov/entrez/query.fcgi?db=OMIM>.

Sclerosteosis is regarded as the most aggressive of the 'benign' type of skeletal dysplasias. Recently, the sclerosteosis (SOST) gene, involved with excessive bone formation in sclerosteosis and Van Buchem disease, was discovered. In 2003 Hamersma, Beighton, and Gardner [2••] reviewed the natural history of 63 patients with sclerosteosis and also compared this condition with Van Buchem disease. Death can occur in young adults due to increased intracranial pressure and sudden coning of the brain. The need for emergency decompression craniec-

**Table 1. Classification of the more frequent sclerosing bone dysplasias**

<b>A. Increased bone density without modification of bone shape</b>
Osteopetrosis
Benign dominant type
Malignant recessive type
Pycnodysostosis
Osteopathia striata with cranial sclerosis
<b>B. Increased bone density with diaphyseal involvement</b>
Progressive diaphyseal dysplasia (Camurati-Engelmann disease)
Craniodiaphyseal dysplasia
Endosteal hyperostosis
Van Buchem disease (hyperostosis corticalis familiaris)
Sclerosteosis
<b>C. Increased bone density with metaphyseal involvement</b>
Craniometaphyseal dysplasia
Frontometaphyseal dysplasia

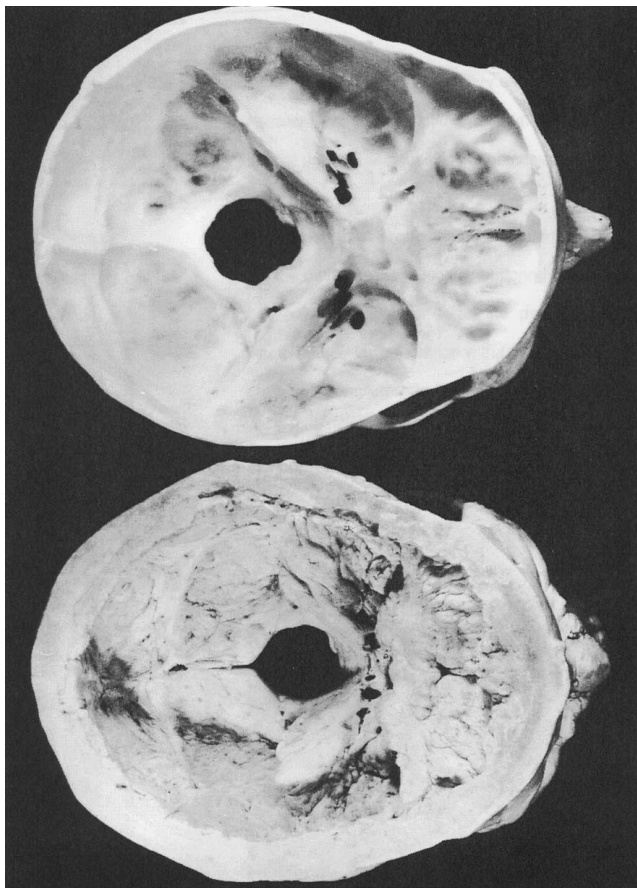tomy should be kept in mind when a patient complains of headache and blurred vision. Van Buchem disease is a similar condition, less aggressive, but craniectomy may also become necessary.

### Neurologic assessment

Complaints of hearing loss, attacks of facial palsy, headaches, sinusitis, facial pain, and obstructed nasal breathing are frequent [3,4,5,6]. Radiologic examination will detect the dense bones in the whole skeleton as well as a sclerotic skull base (Fig. 1) [7]. By age 10 an enlarged skull with frontal bossing becomes evident. The broad nose in craniometaphyseal dysplasia appears even before age six. Enlargement of the mandible develops by age 20, and causes prognathism, which may interfere with closing of the mouth. Decreased facial movement interferes with intelligibility of speech. Dental extractions of malpositioned teeth are difficult. Torus palatini and torus mandibuli can interfere with eating and speech. Nasal obstruction due to thickening of the bony nasal septum and turbinates causes obstruction of nasal breathing. The frontal and ethmoid sinuses are large but the maxillary sinuses are small with frequent maxillary sinusitis.

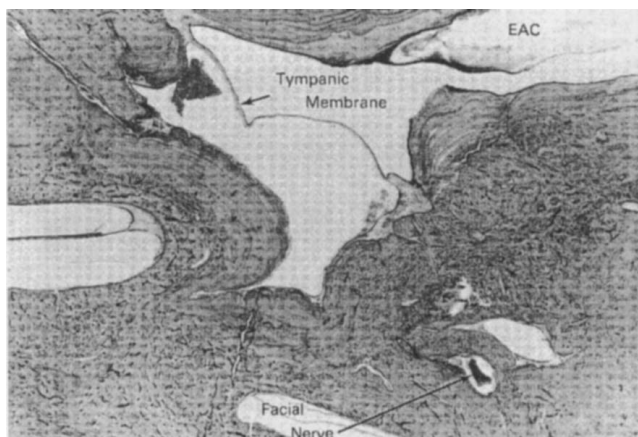
Patients usually have a conductive hearing loss before going to school. Attacks of acute facial palsy can occur at any time. Two patients had a paralyzed face at birth, which recovered partially after 6 months.

The external auditory canal eventually becomes narrow and elongated, placing the tympanic membrane in a deeper position (Fig. 2) [8]. The narrowing of the eustachian tube interferes with ventilation of the middle ear space. The middle ear space becomes markedly reduced due to bony thickening of the promontory of the cochlea as well as the walls of the middle ear. The umbo later on touches the promontory and in the attic movement of the ossicles is impaired due to bony encroachment (Fig. 3) [8]. Early in the disease the stapes becomes fixed and the round window niche narrows down to a pinhead aperture by age five (Figs. 4,5) [8,9].

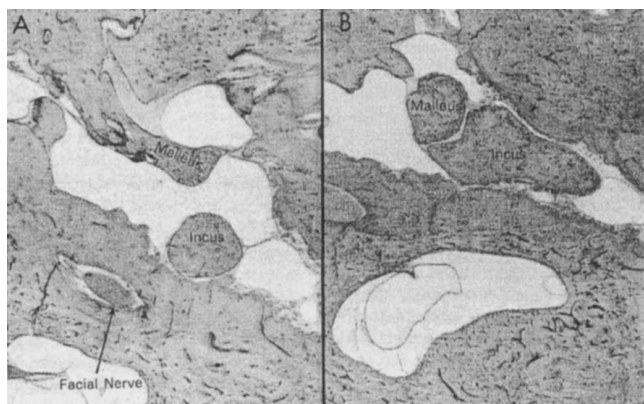
**Figure 1. Normal skull base next to a skull with Van Buchem disease**

Reprinted with permission [7].

Sensorineural hearing loss can occur due to closure of the windows and/or compression of the acoustic nerve inside the internal auditory canal. Temporal bone studies in young adults showed that the acoustic and facial nerves

**Figure 2. External auditory canal**

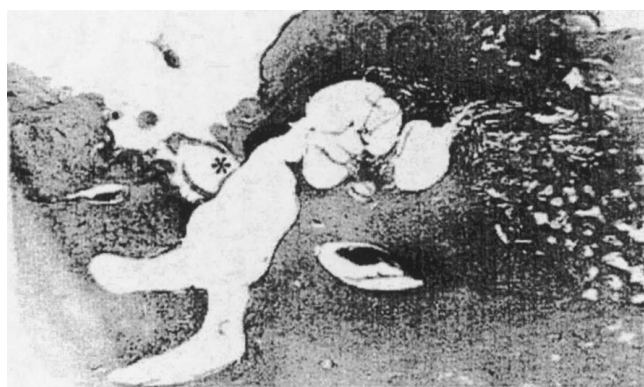
The external auditory canal is narrowed by thick walls of lamellar bone. The Fallopian canal is narrowed and the facial nerve is partly atrophied. Reprinted with permission [8].

**Figure 3. Malleus and body of incus in sclerosteosis**

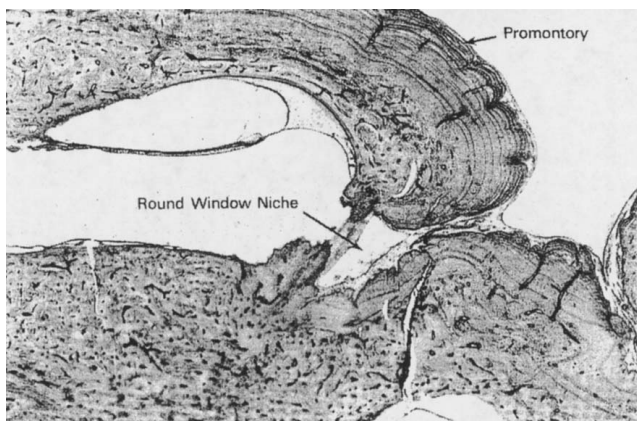
(A) The malleus is ankylosed to the anterior epitympanic wall by a bar of bone. (B) The body of the incus lies wedged in the narrow epitympanic space. Reprinted with permission [8].

were not severely affected in the internal auditory meatus. Total deafness as an end result is rare [10].

The acute facial palsies may recur, but frequently a subsequent attack is on the other side [11]. Invariably the patient is diagnosed as suffering from Bell palsy. Whereas a Bell palsy may be partial or total, the paralysis in a sclerosteosis is always total. Another important difference with Bell palsy is the fact that the nerve always degenerates completely (in Bell palsy less than 20% of total paralyzes progress to total degeneration). After 3 to 5 months the paralysis recovers partially, but sequelae always develop due to faulty re-innervation of the motor nerve (*ie*, incomplete movement of the face, synkinesis, contractures, mass movements, involuntary twitching, and crocodile tearing). Eventually the patient has a compromised facial appearance and has difficulty pronouncing a “p” and “b”. It is thought that the mechanism of the acute attack is occlusion of the veins inside the fal-

**Figure 4. Wedging of the anterior crus of the stapes**

The asterisk highlights the wedging of the anterior crus of the stapes by overgrowth of bone. Reprinted with permission [9].

**Figure 5. Round window niche in sclerosteosis**

The round window niche is overgrown by dense periosteal new bone growth. The promontory and floor of the ear show concentric laminations of lamellar bone. The round window niche is totally blocked. Reprinted with permission [8].

lopien canal, followed by edema and eventual occlusion of the arteries [9].

The most common ocular abnormality is proptosis due to thickening of the orbital walls and vision is usually spared. Optic atrophy and deterioration of vision may occur later on due to pressure on the optic nerve [12].

Other complaints may include gradual loss of smell due to involvement of the olfactory nerve, excruciating facial pain, and wasting of masticatory muscles due to involvement of the trigeminal nerve. Impaired balance and vertigo are rare complaints but when vestibular tests are done, vestibular responses are found to be reduced [13]. This may be attributed to the slow process of bony growth. Ataxia is rare and endolymphatic hydrops has not been encountered. Chronic back pain due to compression of the roots of the spinal cord occurs frequently. In addition the patient may present with chronic headaches secondary to increased intracranial pressure. Papilledema may then be found at funduscopy. Patients may also present with cerebrospinal fluid rhinorrhea but meningitis is rare. This may be due to the increased pressure of the cerebrospinal fluid. Death often occurs due to medullary coning. The intellect of most patients remains normal.

### Management

Surgical treatment is currently the cornerstone of the management of symptoms and complications of excessive bony overgrowth.

Correction of hearing loss is difficult and only has limited success. The biggest problem is closure of the round window, and drilling away the overhang of bone can damage the high frequencies of hearing. Freeing of ossicles in childhood is usually temporary until the rapid

growth of bone fixates it again. Drilling out the oval window may become necessary. The annulus of the windows usually stays the same size because bony overgrowth occurs on the outer surface of the otic capsule and spares the annulus. The incus and the head of the malleus usually have to be removed. Malleovestibulopexy has limited success due to bony ankylosis of the umbo with the promontory of the cochlea.

Patients usually end up wearing hearing aids. Widening of the external auditory canal is usually necessary to accommodate it. If the patient does not hear with a hearing aid, both oval and round window may be closed, and one of them must be opened surgically. Bone-anchored hearing aids have recently been used with success in a patient with Van Buchem disease [14]. Cochlear implantation for audiologic rehabilitation has been described in Camurati-Engelmann disease [15].

Decompression of the vestibular nerve for dizziness has been described and trigeminal nerve decompression can help if facial pain is severe [16].

The first total decompression in a patient with facial nerve palsy due to bony dysplasia was performed by William House in Los Angeles in 1969, followed by Fisch (Zürich), who operated on three South African patients [17–19]. Hamersma has performed total decompression in 30 ears with sclerosteosis, the youngest being 2 years old. The experience over 26 years has been that total decompression can prevent future attacks of facial paralysis in sclerosteosis [20]. Surgery is technically difficult due to a sclerotic mastoid and small or absent antrum, as well as the thick dome of the skull (15–25 mm thick). The diameter of the facial nerve in the labyrinthine and tympanic segment is reduced to 0.3 mm. The best time for surgery is before age six. Due to the reduced ventilation of the middle ear space, retraction pockets can develop in the posterior tympanotomy performed during decompression of the mastoid portion of the facial nerve. The ‘canal wall down’ technique is advised because the ‘open’ mastoid cavity remains small due to new bone formation.

Orbital decompression for proptosis may be used but postoperative blindness has been encountered. A lateral approach to the orbit usually has more chance of success than unroofing of the orbit.

Sudden death due to medullary coning can occur in young adults with sclerosteosis. Decompressing the brain by means of an emergency posterior fossa craniectomy can prevent death. This usually needs to be followed up by craniectomy of the frontal and parietal skull bone, as well as widening of the foramen magnum [21].

Other surgical options are reduction surgery of the mandible for cosmetic and functional purposes, decompression of the spinal cord to alleviate severe root pains, and surgery to correct other skeletal deformities such as syndactyly in sclerosteosis.

Nonsurgical management is limited and currently restricted to a few cases described in the literature. Steroid (Deflazacort) treatment for children with Camurati-Engelmann disease, and the use of bone marrow transplantation and stem cell transplantation in recessive “malignant” osteopetrosis has been mentioned in the literature [22,23]. Decompression of cranial nerves or the orbit is seldom indicated in the recessive “malignant” form of osteopetrosis.

## Conclusion

For the practicing otolaryngologist the importance of sclerosing bone dysplasias is the knowledge of such an entity and to include it in the differential diagnosis when treating patients with neural deficits. In children and young adults suffering from recurrent or alternating facial nerve palsy, thickened bone must be excluded as a possible cause. Although we are currently treating the manifestations of the disease, the answer and possible cure lies in the manipulation of the genetic basis underlying these disorders.

## References and recommended reading

Papers of particular interest, published within the annual period of review, have been highlighted as:

- Of special interest
  - Of outstanding interest
- 1 Brunkow ME, Gardner JC, Hamersma H, et al.: Bone dysplasia sclerosteosis results from loss of the SOST gene product, a novel cystine knot-containing protein. *Am J Hum Genet* 2001, 68:577–589.
  - 2 Hamersma H, Gardner J, Beighton P: The natural history of sclerosteosis. *Clin Genet* 2003, 63:192–197.  
This original overview article highlights the manifestation and natural history of sclerosteosis. It contains photographic illustrations of certain clinical features of the disease.
  - 3 Beighton P, Barnard A, Hamersma H, van der Wouden A: The syndromic status of sclerosteosis and van Buchem disease. *Clin Genet* 1984, 25:175–181.
  - 4 Steward CG: Neurological aspects of osteopetrosis. *Neuropathol Appl Neurobiol* 2003, 29:87–97.  
This review article highlights the neurological aspects of osteopetrosis in a systematic manner.
  - 5 Kocher MS, Kasser JR: Osteopetrosis. *Am J Orthop* 2003, 32:222–228.
  - 6 Klintworth GK: The neurologic manifestations of osteopetrosis (Albers-Schönberg disease). *Neurology* 1963, 13:512–519.
  - 7 Van der Wouden A: Hyperostosis corticalis familiaris. In *Botziekten in het os temporale met gehoorstoornissen*. The Hague: Mouton and Co; 1971:11–49.
  - 8 Schucknecht HF: Disorders of bone. In *Pathology of the Ear*, edn 2. Schucknecht H.F.; Philadelphia: Lea & Febiger; 1993:365–414.
  - 9 Dort JC, Pollak A, Fisch U: The fallopian canal and facial nerve in sclerosteosis of the temporal bone: a histopathologic study. *Am J Otol* 1990, 11:320–325.
  - 10 Nager GT, Hamersma H: Sclerosteosis involving the temporal bone. *Histopathologic aspects*. *Am J Otolaryngol* 1986, 7:1–16.

- 11 Hamersma H, May M: Osteopetrosis and other bone disorders causing facial palsy. In *The Facial Nerve*. Edited by May M, Schaitkin BM. New York-Stuttgart: Thieme; 2000:409–421.
- 12 Singh SK, Singh R, Mayrya VK: Primary optic atrophy and autosomal dominant osteopetrosis type II. *J Assoc Physicians India* 2002, 50:850.
- 13 Hanson W, Parnes LS: Vestibular nerve compression in Camurati-Engelmann disease. *Ann Otol Rhinol Laryngol* 1995, 104:823–825.
- 14 Personal communication: Dikkers FG, personal communication.
- 15 Friedland DR, Wackym PA, Rhee JS, Finn MS: Cochlear implantation for auditory rehabilitation in Camurati-Engelmann disease. *Ann Otol Rhinol Laryngol* 2000, 109:160–162.
- 16 Hellier WP, Brookes GB: Vestibular nerve dysfunction and decompression in Engelmann's disease. *J Laryngol Otol* 1996, 5:110.
- 17 Miyamoto RT, House WF, Brackmann DE: Neurotologic manifestations of the osteopetrosis. *Arch Otolaryngol* 1980, 106:210–214.
- 18 Personal communication: House W, personal communication.
- 19 Fisch U: Operations on the facial nerve in its labyrinthine and meatal course. In *Surgery of the Facial Nerve*. Edited by Miehleke A. W.B. Saunders; 1973: 21–32 and 196–198.
- 20 Hamersma H: Total decompression of the facial nerve in osteopetrosis. *ORL* 1974, 36:21–32.
- 21 De Villiers JC, Du Plessis JJ: Neurosurgical management of sclerosteosis. In *Operative Neurosurgical Techniques*. Edited by Schmidek, Sweet. Philadelphia: WB Saunders Co; 1995:2141–2152.
- 22 Heymans O, Gebhart M, Alexiou J, Sokolow Y: Camurati-Engelmann disease. Effects of corticosteroids. *Acta Clin Belg* 1998, 53:189–192.
- 23 Steward CG, Pellier I, Mahajan A, et al.: Severe pulmonary hypertension: a frequent complication of stem cell transplantation for malignant infantile osteopetrosis. *Br J Haematol* 2004, 124:63–71.